


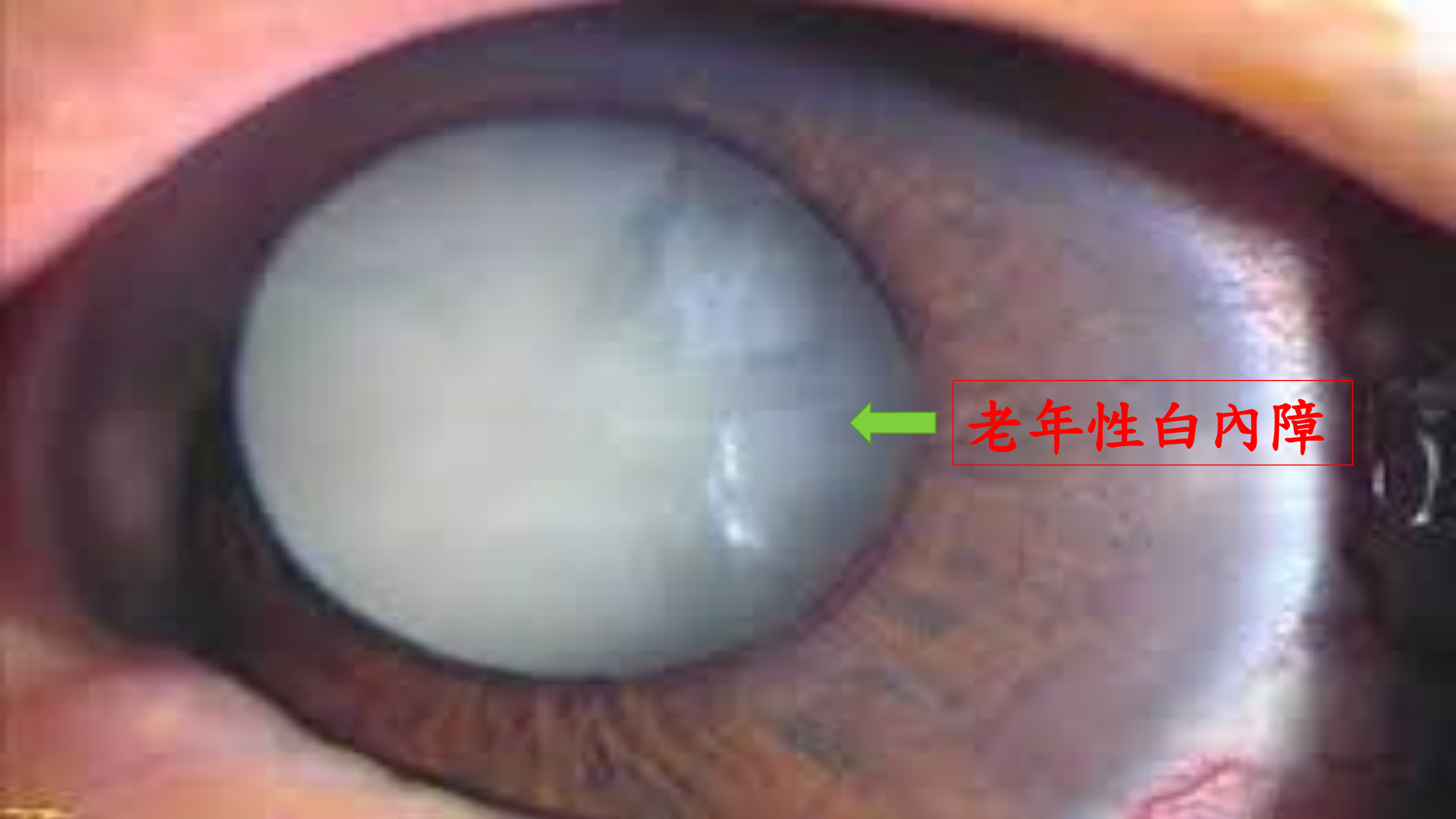年長者視力問題
白內障
青光眼
黃斑部病變

106-08-17

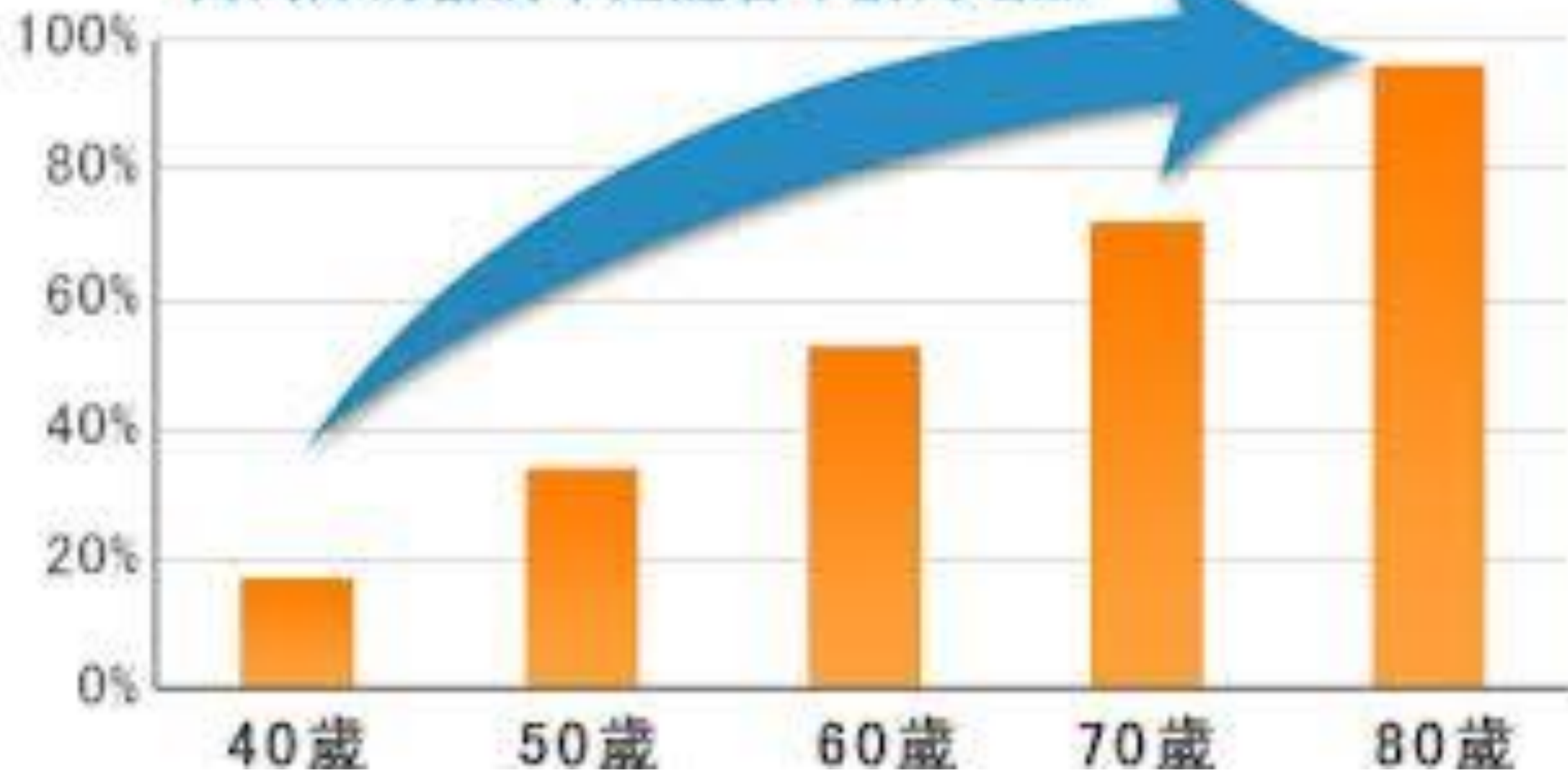
行政院退輔會八德榮家負責醫師
國立中央光電博士
國立陽明醫學院醫學系
教育部視力保健種子醫師
張華明醫師

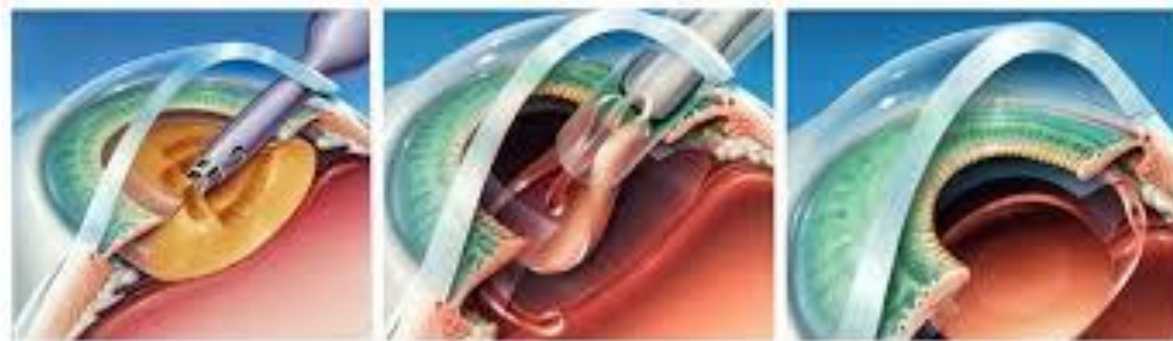



老年性白內障

白內障的發病率是隨著年齡而增加







步驟一
使用超音波乳化儀，將混濁水晶體乳化後真空吸出

步驟二
植入新式多焦點非球面人工水晶體於晶體囊袋內

步驟三
取代原有的水晶體



馬爾濟斯10歲，因糖尿病引起雙眼白內障（成熟期）失明



馬爾濟斯10歲，因糖尿病引起雙眼白內障（成熟期）失明。術前裂隙燈顯微鏡檢查水晶體混濁，以超音波乳化術移除混濁水晶體，但未植入人工水晶體。術後3個月追蹤可見眼底反光並恢復視力



A



B



C



D



E



F



G



H



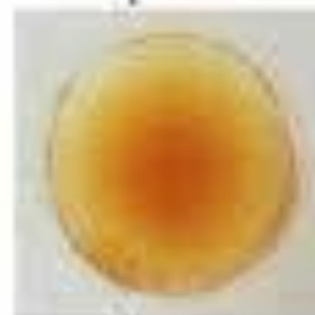I



J



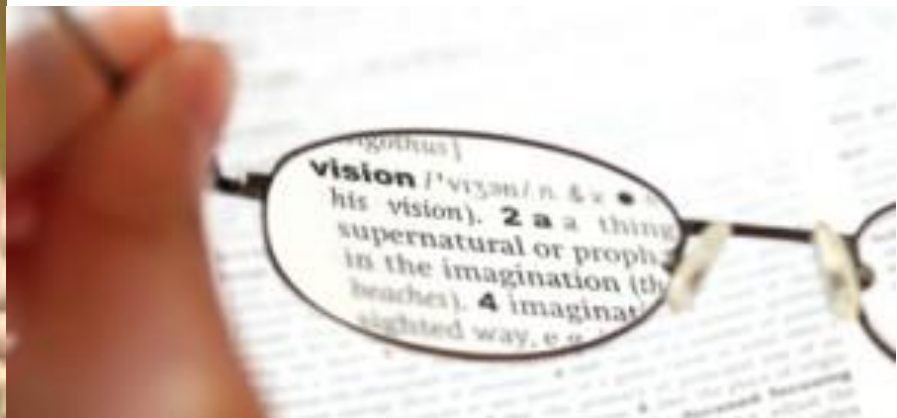K



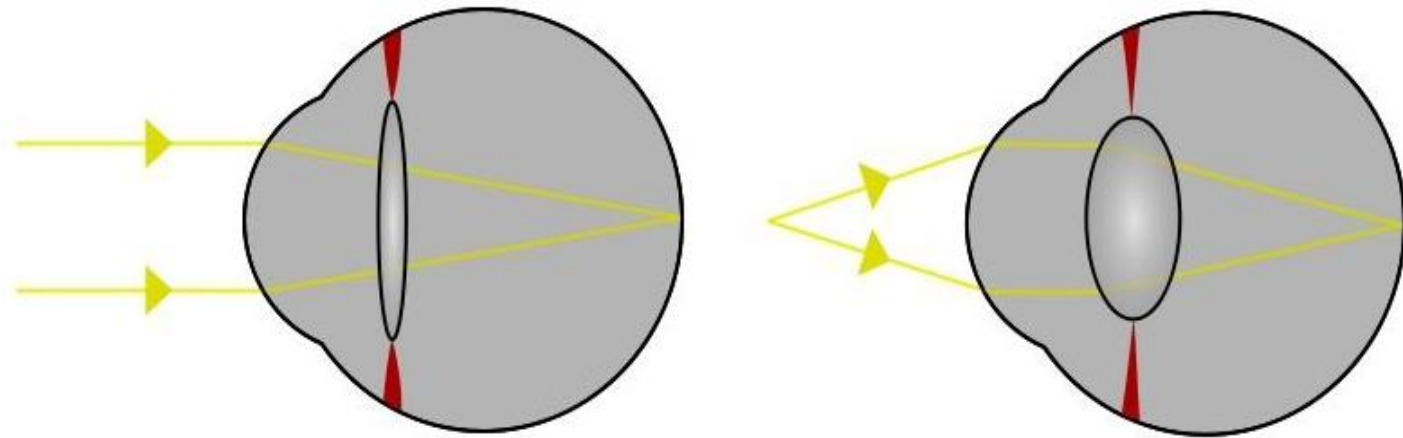
L



二、老花眼



調節的機制



年齡	調節力(+度數)	老花度數(+度數)
45	300度	100度
50	200度	200度
55	100度	250度
60	50度	300度
65	25度	350度
70	25度	375度
75	0度	400度

5招防止老花眼提早報到



1) 眼睛按摩。



2) 溫敷眼睛。



3) 眼睛運動。



4) 營養補充。



5) 減少用眼負擔。

● 小提醒

由於溫度保持良好的距離，才能使用眼睛更久呢！





三、青光眼


青光眼的視力模糊

正常視野



© TOPIC/Corbis. All rights reserved. www.topicphoto.com

初期青光眼視野



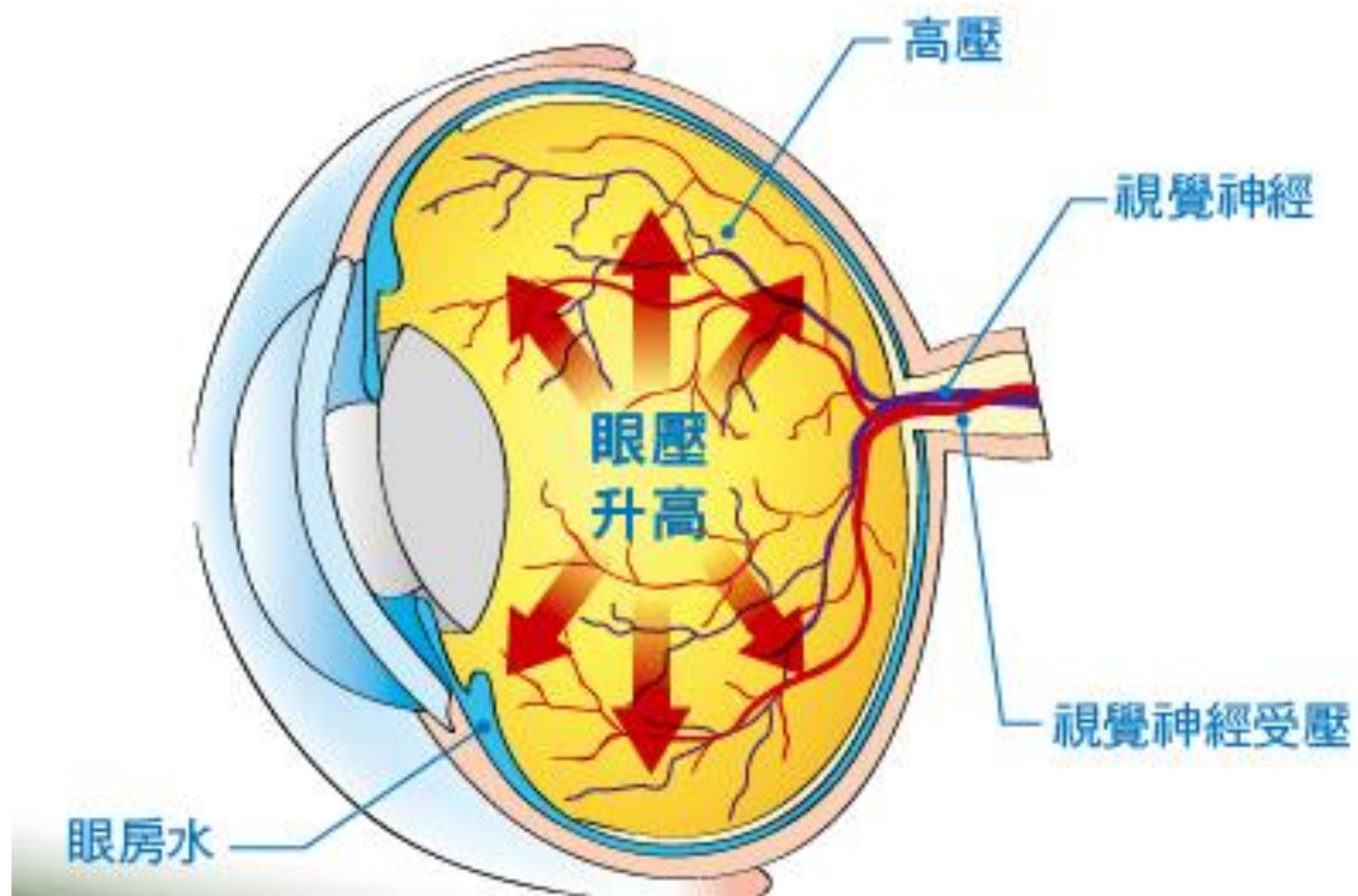
© TOPIC/Corbis. All rights reserved. www.topicphoto.com

中度青光眼視野



末期青光眼視野



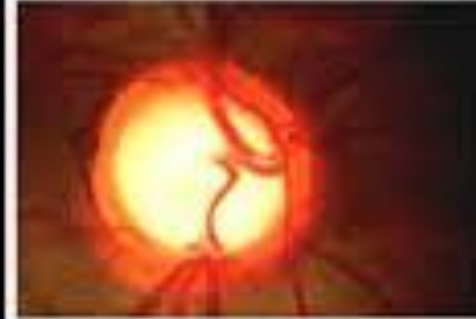
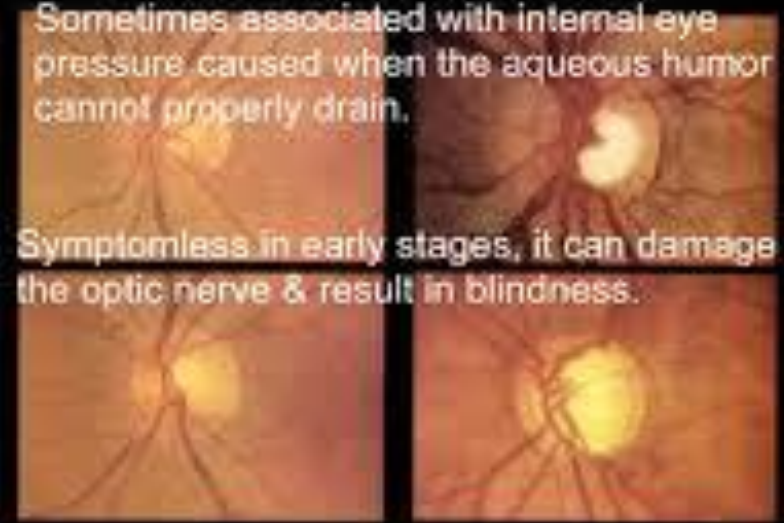


Glaucoma...

...is damage to the optic nerve.

Sometimes associated with internal eye pressure caused when the aqueous humor cannot properly drain.


Symptomless in early stages, it can damage the optic nerve & result in blindness.



Normal field of vision



Field of vision decreased from glaucoma





四、老人性黃斑部病變



Normal Vision



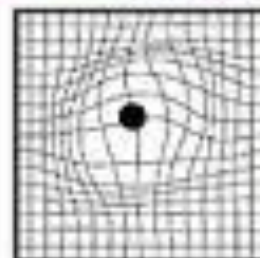
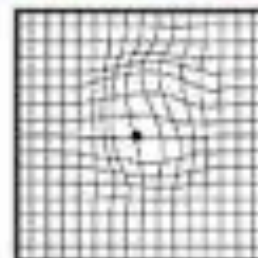


Vision with age-related macular degeneration

The progression of wet AMD



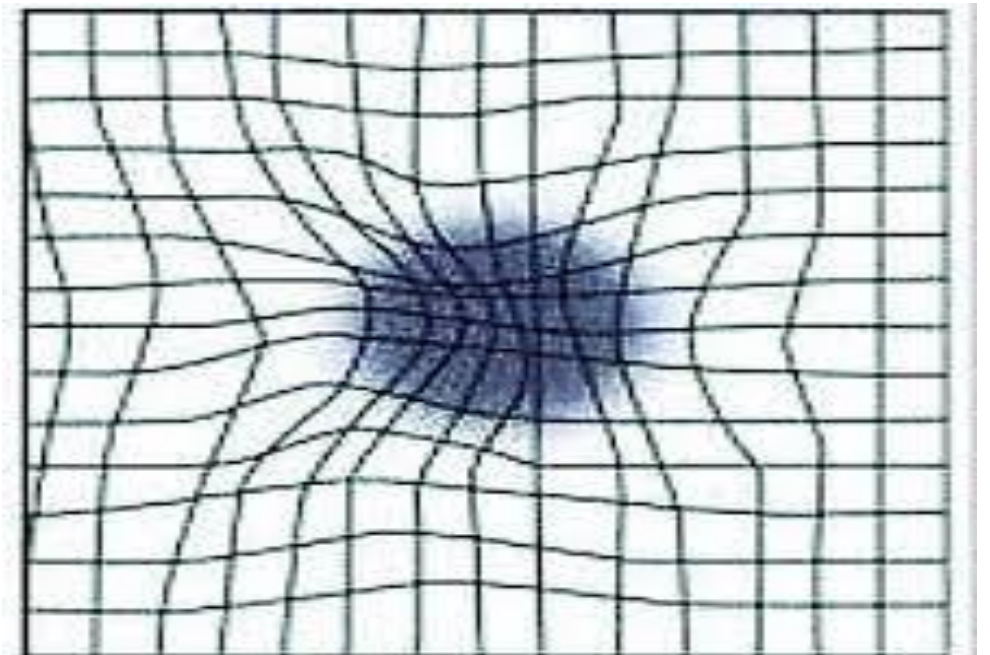
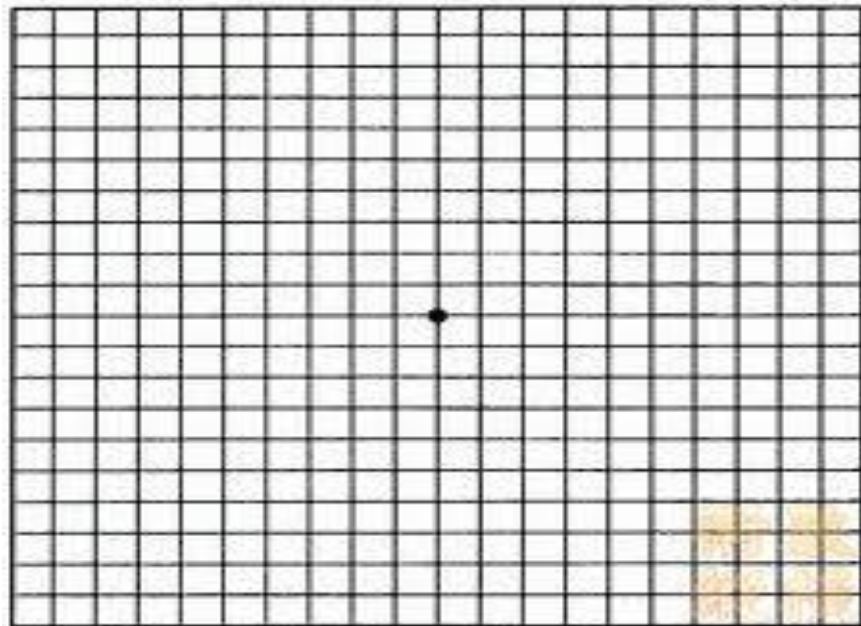
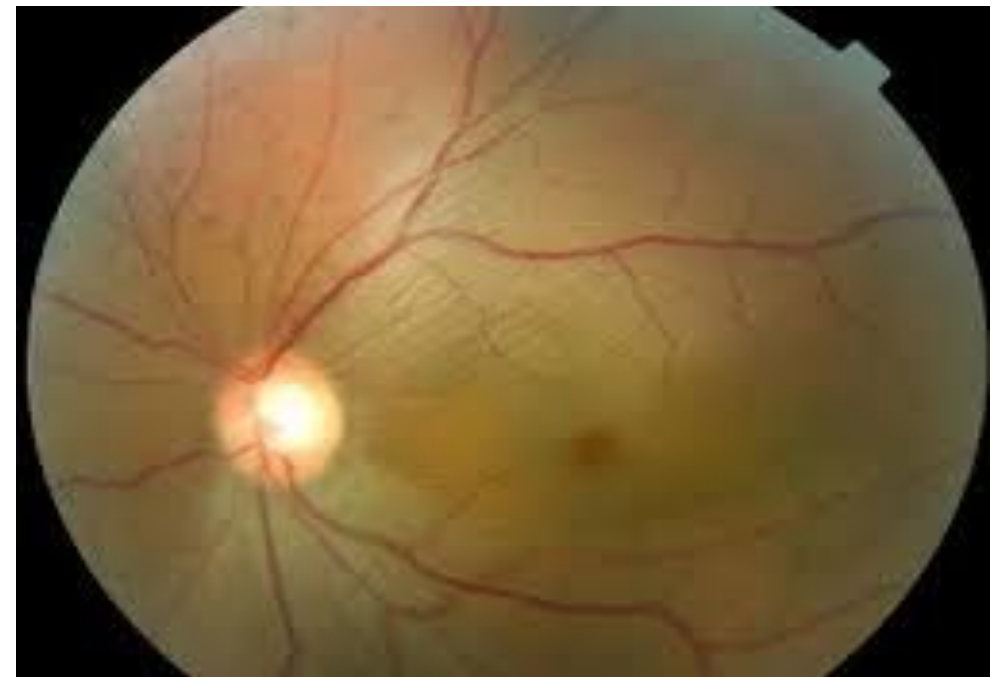
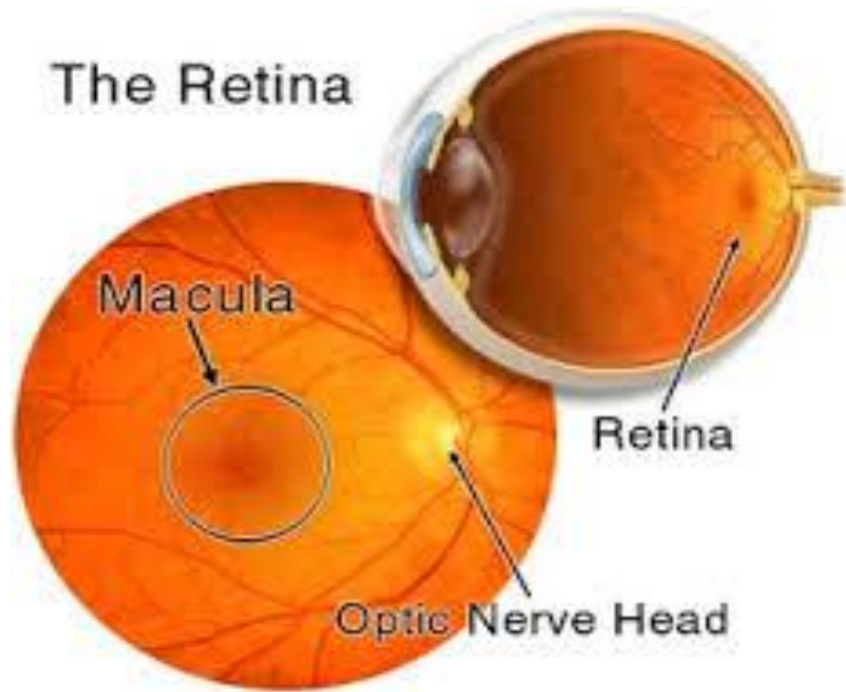
Normal vision

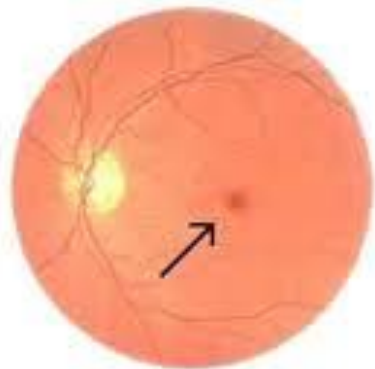
Wet AMD



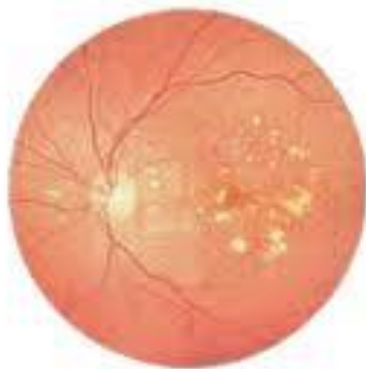Amsler grid

The Retina

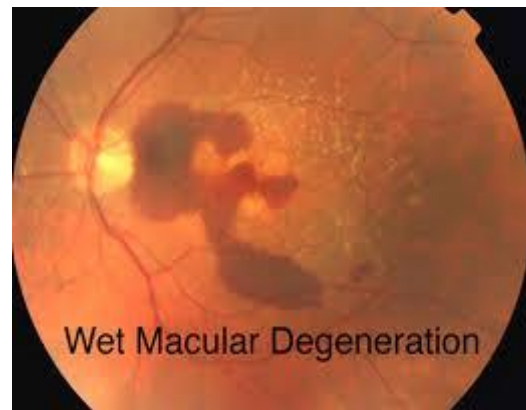




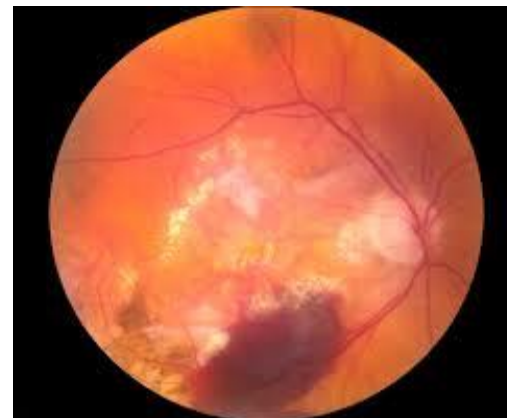Normal Macula



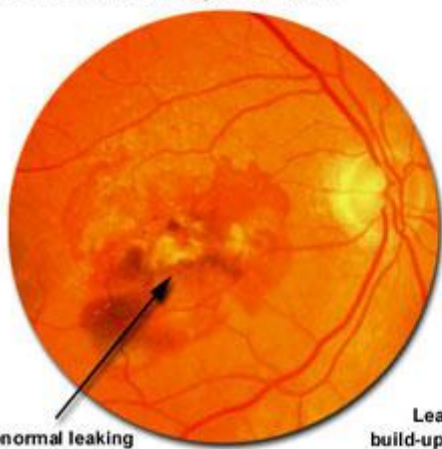
Macular Degeneration



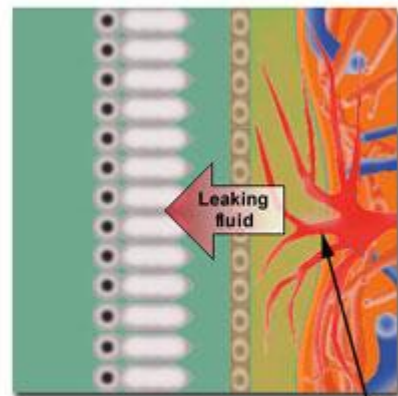
Wet Macular Degeneration



"Wet" Macular Degeneration

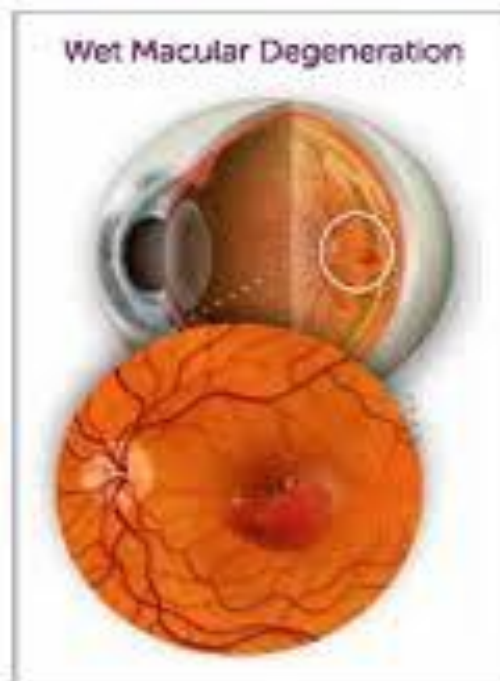


Abnormal leaking blood vessels

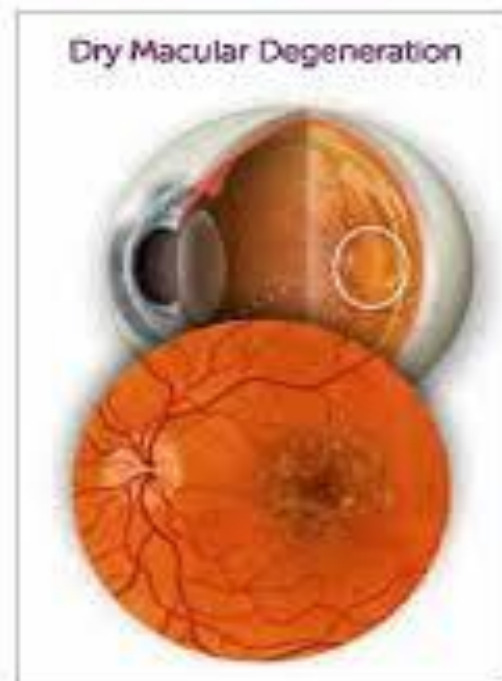

Leaking blood vessels cause fluid build-up, detaching cone and pigment cells. Vision loss can be sudden.

Abnormal leaking blood vessels



Wet Macular Degeneration



Dry Macular Degeneration